

## Balloon-Guided Needle Puncture with Contrast Enhancement in the Presence of Ipsilateral Subclavian Vein Occlusion

Mohammadbagher Sharifkazemi\*, Saiyyid Hamid

Cardiology Department, Nemazee Hospital, Zand Blvd, Shiraz, Iran

**Correspondence to:** Mohammadbagher Sharifkazemi, Cardiology Department, Nemazee Hospital, Zand Blvd, Shiraz, Iran. E-mail: Md\_Sharifkazemi@gmail.com

**Received:** March 20, 2023; **Accepted:** April 23, 2023; **Published:** April 30, 2023

**Citation:** Sharifkazemi M. Balloon-Guided Needle Puncture with Contrast Enhancement in the Presence of Ipsilateral Subclavian Vein Occlusion. J Cardiol Cardiovasc Dis. 2023;1(1):21-26.

**Copyright:** © 2023 Sharifkazemi M. This is an open-access article distributed under the terms of the Creative Commons Attribution License, which permits unrestricted use, distribution, and reproduction in any medium, provided the original author and source are credited.

### ABSTRACT

This report aims to share our experience with a new technique for safe needle puncturing in patients with venous obstruction in the subclavian or brachiocephalic vein on the same side. Between June 2016 and June 2018, eleven patients, eligible for cardiac implantable electronic devices implantation or upgrade, underwent this innovative procedure. All patients had confirmed subclavian vein obstruction through ipsilateral phlebography. The technique involved inserting a guiding catheter from the femoral vein into the brachiocephalic vein, performing retrograde brachiocephalic venography, and passing a guidewire. An over-the-wire balloon was then guided along the wire, serving as a marker for needle puncturing. Needle puncturing attempts (ranging from one to three) were made to successfully access the vein. Subsequently, the valve peel-away sheath(s) was/were introduced over the guidewire, and placed through the needle, and the lead(s) was/were positioned conventionally. Remarkably, no complications occurred during the procedure, saving valuable time. This contrast-filled balloon-guided needle puncturing technique, utilized in the presence of ipsilateral subclavian vein obstruction, has proven to be a secure and viable method.

**Keywords:** Ipsilateral subclavian vein obstruction; Retrograde subclavian/brachiocephalic phlebography; Contrast filled balloonguided venepuncture.

### INTRODUCTION

The pioneering use of surgical techniques for pacemaker implantation dates back to October 8, 1958, when Senning and Elmqvist in Sweden performed the first pacemaker insertion. They utilized a thoracotomy to suture two epicardial electrodes, placing the 'definitive' unit in the abdominal wall of the recipient. In the subsequent years, surgeons continued to play a pivotal role in pacemaker implantation until advancements in technology led cardiologists to perform non-surgical implantations as generators reduced in size [1-4].

As cardiac patients' lifespans increased and technologies like Implantable Cardioverter Defibrillators (ICD) and Cardiac Resynchronization Therapy (CRT) emerged, devices with larger generators and multiple leads became commonplace. However, cardiologists faced challenges, particularly in younger and slimmer patients with narrower subclavian veins, leading to increased risks of stenosis or vein obstruction after lead insertion.

Various methods exist for finding suitable veins for non-surgical cardiac lead insertions, including percutaneous needle vein puncturing via approaches like cephalic, axillary, or subclavian veins [5,6]. The chosen technique eventually necessitates passage through the subclavian vein, with a preference for the left side due to the prevalence of right-handed patients.

Anatomically, the subclavian vein forms at the intersection of two veins: the deep axillary vein from below and the superficial cephalic vein from above, becoming the subclavian vein after crossing the outer edge of the first rib. Subsequently, the subclavian vein intersects with the internal jugular vein, forming the brachiocephalic vein, a bilateral structure in veins.

Historically, in 1952, Aubaniac R introduced the subclavian vein puncture technique, now typically performed at the intersection of the first rib and clavicle under fluoroscopy. Contrast agent-enhanced phlebography aids in visualizing vessel pathways, enhancing safety, and reducing complications like pneumothorax.

For ICD and CRT-D devices, left-side generator placement is preferred, allowing for efficient targeting of the heart's electrical circuit and coronary sinus ostia intubation. However, complications arise in cases of subclavian vein obstruction. Patients with prolonged hospital stays, intravenous drug administration through upper limb cannulas, or those undergoing device upgrades face higher risks of subclavian vein occlusion, with an incidence of up to 9.0%.

A prospective study in 2007 reported a 14.0% prevalence of subclavian stenosis and/or thrombosis among 150 patients undergoing ICD or pacemaker implantation, emphasizing the significance of addressing subclavian vein issues in device procedures [7-9].

## **METHODS**

Between June 2016 and June 2018, our center encountered several patients seeking new cardiac implantable electronic devices (CIEDs) or device upgrades. Among them, eleven patients faced challenges, all except one who suffered from marked obesity and prolonged hospital stay, had previously undergone lead insertion in the subclavian vein. To address this issue, we utilized a technique outlined below.

### Description of the Technique

#### 1. Retrograde Entry of the Guiding Catheter:

We introduced a number seven F sheath into the femoral vein and navigated the guiding catheter, tracking a 0.035" guidewire, reaching the left brachiocephalic vein through the iliac vein, inferior vena cava, right atrium, and superior vena cava. Retrograde localized phlebography was performed using a 20 cc contrast agent (visipaque 300 mg).

#### 2. Retrograde Introducing the Guidewire:

Using a hydrophilic 0.035" guidewire (180 cm length), or if necessary, a hydrophilic 0.014" guidewire (300 cm length), we advanced as far as possible to the proximal part of the subclavian vein retrogradely.

#### 3. Choosing the Balloon Type:

For complete vein obstruction, an over-the-wire (OTW) noncompliant peripheral balloon was used. In cases of partial occlusion, an over-the-wire coronary balloon was employed.

#### 4. Balloon Filling with Contrast Agent:

The balloon was filled with contrast agent (visipaque 300 mg). This step served two purposes: making balloon targeting with a standard needle easier in a three-dimensional space and reducing the number of needle punctures to a range of 1-3.

#### 5. Balloon-Guided Needle Puncturing:

Balloon-guided puncturing was performed using an 18 G needle. Upon blood arrival in the syringe, confirming needle tip placement inside the vein, the 0.035? guidewire could be inserted easily, allowing for the insertion of the intravenous valve peel-away sheath(s) without complications.

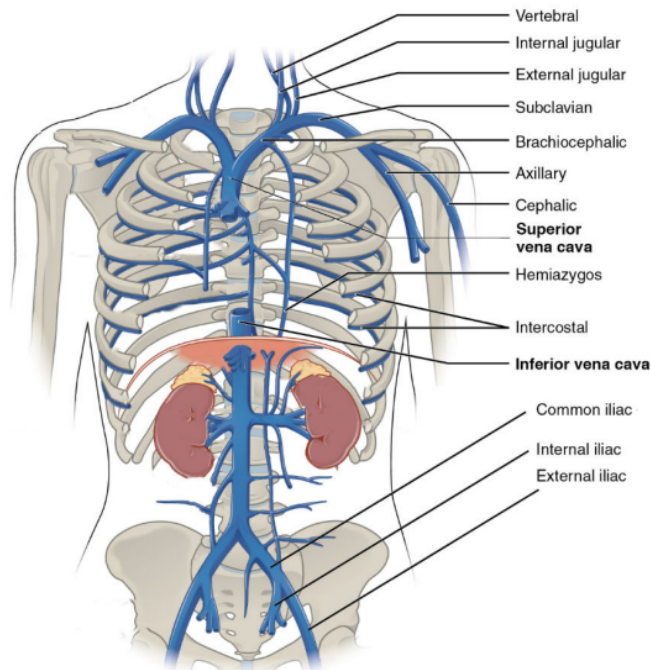
6. Retrieval of the Retrograde Guiding Catheter and Its Adjuvants: After confirming the insertion of the sheath(s) into the subclavian or brachiocephalic vein, the entire guidewire, balloon, and guiding catheter were retrieved from the femoral sheath [10-11].

## RESULTS

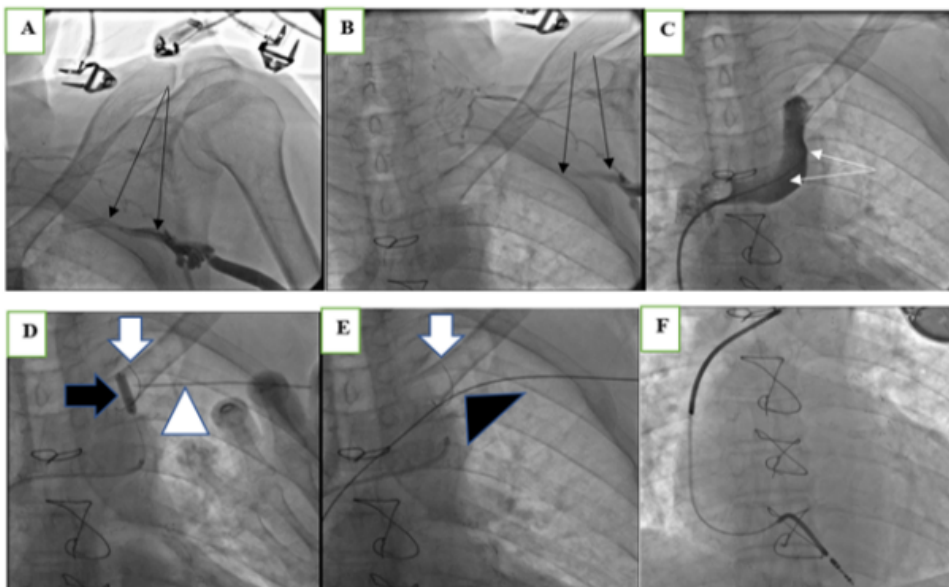
This technique enabled successful access to the occluded subclavian vein while minimizing the risk of complications, providing an effective solution for our patients.

Eleven patients were attempted, all of them with subclavian vein near complete obstruction (7 out of 11) or total complete obstruction (4 out of 11). The length of time from the first lead insertion in the study patients to these procedures was from one to seven years in ten patients.

The clinical characteristics of the study patients are listed. To reach the balloon, the number of needle puncturing was respectively: once in one patient, twice in seven patients and three times in three patients. To reduce the number of needle punctures, we used the double-wire method in three patients. This is achievable by introducing a sheath over the guidewire, taking out the dilator, putting the second guidewire into the introducer sheath and taking out the whole introducer sheath. Therefore, two guidewires remained inside the subclavian vein, we can introduce one valve peel away sheath over each wire and then use it for each lead in turn separately [9]. All procedures on eleven patients were successful and none of them had acute complications such as pneumothorax and bleeding or subacute complications such as infection (Figures 1 and 2).



**Figure 1:** Normal anatomy of upper thoracic veins with a focus on the left-sided major veins and their relation to the chest cage bones. Image modified by author. From Anatomy and Physiology by Rice University.



**Figure 2:** Seventy-four-old gentleman with a history of several times prolonged hospital admissions, scheduled for ICD-VR implantation because of aborted sudden cardiac death.

## DISCUSSION

Implanting or upgrading devices for patients with subclavian vein occlusion presents a challenging scenario for electrophysiologists. The occurrence of subclavian vein obstruction, though rare, complicates procedures, increasing the risk of complications. The incidental discovery of subclavian vein obstruction is reported in approximately 0.6% of cases and rises to 10.0% in patients under a hemodialysis program without a history of catheter placement.

Various methods have been proposed to address complete obstruction, each with its advantages and drawbacks. Using contralateral veins and implanting a new system can lead to an increased number of leads in the superior vena cava, which the Heart Rhythm Society recommends limiting to no more than four. Inserting leads into the opposite side vein and tunneling it towards the pocket under the subcutaneous tissue risks damage to internal mammary arteries due to large caliber leads like ICD leads. The excimer laser method, although suggested in some reports, is not universally available. Supraclavicular or internal jugular vein punctures involve tunneling over the clavicular bone and have long-term risks of lead damage due to low subcutaneous tissue content. Surgical techniques using epicardial leads pose significant risks to patients, especially those with low EF, and have lower durability. Leadless pacemakers, a recent development, are not widely used, and their long-term performance remains unclear. Other procedures, such as using excimer lasers to retrieve old leads or iliofemoral vein punctures to introduce leads, have been suggested but lack promising outcomes.

In a study by Konstantinos et al., it was reported that having previous leads and reimplanting pacemaker generators are risk factors for pocket infections. However, our technique, involving fewer needle punctures, shorter procedure duration, and reduced hematoma formation, might minimize the risk of infection. Although further studies with more patients and longer follow-up periods are needed to validate this claim, our innovative contrast-filled balloon-guided needle puncturing technique has demonstrated success and safety, providing a solution to this challenging clinical scenario.

## CONCLUSION

In conclusion, our contrast-filled balloon-guided needle puncturing technique, used in the presence of ipsilateral subclavian vein obstruction, proves to be a safe and feasible method for patients requiring pacemaker and ICD implantations or upgrades. This technique could also benefit patients with morbid obesity or chronic kidney disease requiring catheter insertion. There were no conflicts of interest for this study, and no specific grants were received from any funding agency.

## FUNDING

This work did not receive any specific grant from any funding agency in the public, commercial, or not-for-profit sector.

## CONFLICTS OF INTEREST

There are no conflicts of interest for the present study.

## REFERENCES

1. Richard HM, Selby JB, Gay SB, Tegtmeyer CJ (1992) Normal venous anatomy and collateral pathways in upper extremity venous thrombosis. *Radiographics* 12: 527-534.
2. *Anatomy and Physiology* (2016) OpenStax CNX.
3. Aubaniac R (1952) Subclavian intravenous injection: Advantages and technic. *Presse Med* 60: 1456.
4. Marine JE, Brinker JA (2014) Techniques of pacemaker implantation and removal. *Cardiac pacing and ICDs* 150-210.
5. Shimada Y, Matsukawa M, Yamamoto F (2008) Subpectoral technique of pacemaker implantation-reduction of cost and length of hospital stay. *J Rural Med* 3: 15-18.

6. Lickfett L, Bitzen A, Arepally A, Nasir K, Wolpert C, et al. (2004) Incidence of venous obstruction following insertion of an implantable cardioverter defibrillator A study of systematic contrast venography on patients presenting for their first elective ICD generator replacement. *Europace* 6: 25-31.
7. Korkeila P, Nyman K, Ylitalo A, Koistinen J, Karjalainen P, et al. (2007) Venous obstruction after pacemaker implantation. *Pacing Clin Electrophysiol* 30: 199-206.
8. Burri H (2015) Overcoming the challenge of venous occlusion for lead implantation. *Indian Pacing Electrophysiol J* 15: 110-112.
9. Rajappan K (2009) Permanent pacemaker implantation technique: Part I. *Heart* 95: 259-264.
10. Gonsalves CF, Eschelmann DJ, Sullivan KL, DuBois N, Bonn J (2003) Incidence of central vein stenosis and occlusion following upper extremity PICC and port placement. *Cardiovasc Intervent Radiol* 26: 123-127.
11. Oguzkurt L, Tercan F, Yildirim S, Torun D (2005) Central venous stenosis in haemodialysis patients without a previous history of catheter placement. *Eur J Radiol* 55: 237-242.