

## Experience with Percutaneous Coronary Intervention for Isolated Left Main Coronary Artery Disease at a Single Center

**Moniruzzaman Ali\***

Consultant Cardiology, Sheikh Fazilatunnessa Mujib Memorial KPJ Specialized Hospital, Gazipur, Dhaka, Bangladesh

**Correspondence to:** Moniruzzaman Ali, Consultant Cardiology, Sheikh Fazilatunnessa Mujib Memorial KPJ Specialized Hospital, Gazipur, Dhaka, Bangladesh. E-mail: ali.md@gmail.com

**Received:** March 26, 2023; **Accepted:** April 18, 2023; **Published:** April 25, 2023

**Citation:** Ali M. Experience with Percutaneous Coronary Intervention for Isolated Left Main Coronary Artery Disease at a Single Center. J Cardiol Cardiovasc Dis. 2023;1(1):16-20.

**Copyright:** © 2023 Ali M. This is an open-access article distributed under the terms of the Creative Commons Attribution License, which permits unrestricted use, distribution, and reproduction in any medium, provided the original author and source are credited.

### ABSTRACT

**Objective:** Isolated left main coronary artery disease (ILMCAD) is rare, and while coronary artery bypass graft surgery (CABG) has traditionally been considered the standard treatment for left main coronary stenosis (LMCA), real-world studies suggest that percutaneous coronary intervention (PCI) could be a safe and viable alternative for patients with ILMCAD.

**Methods:** This prospective observational study, conducted from February 1, 2021, to January 31, 2022, enrolled 10 patients diagnosed with Angina or NSTEMI and isolated left main coronary artery disease as revealed by coronary angiography (CAG). All patients underwent PCI using newer generation drug-eluting stents (DES), and their outcomes were monitored for six months.

**Results:** The study included 10 patients with a mean age of  $44.1 \pm 6.6$  years. Among them, 7 (70%) were male, and 3 (30%) were female. Hypertension (70%) was the most common risk factor, followed by smoking (60%), dyslipidemia (60%), diabetes mellitus (50%), and a positive family history of ischemic heart disease (50%). Of the 10 patients, 7 (70%) had chronic stable angina, and 3 (30%) had NSTEMI. Lesions were distributed as follows: ostial left main (30%), shaft involvement (30%), distal left main disease (20%), and whole segment disease (20%). The mean SYNTAX score was  $11.1 \pm 1.1$ , with the majority of patients having a low SYNTAX score. All patients received newer generation DES implantation, and post-procedural outcomes were satisfactory. No patients experienced Major Adverse Cardiovascular Events (MACE) during the study period.

**Conclusion:** Left main PCI using newer generation DES proves to be a suitable option with favorable outcomes for treating patients with isolated left main coronary artery disease.

**Keywords:** ILMCAD-Isolated Left Main Coronary Artery Disease; PCI-Percutaneous Coronary Intervention; CABG-Coronary Artery Bypass Graft

## INTRODUCTION

Significant isolated left main coronary artery stenosis (ILMCA) is a life threatening condition. It is found in 3–10% of the patients undergoing coronary angiogram [1,2]. PCI has long been tried as an alternative option in treatment of LM coronary artery disease. PCI with bare metal stents (BMS) were found to have low-procedural complications but they had unacceptably higher rate of repeat revascularization rate [3-6]. Since the advent of drug eluting stents (DES) in 2002, with the promise of vastly reduced rate of in stent restenosis, there has been a resurgence of interest of ILMCA stenting. Several registries from different parts of the world have shown comparable short-term outcomes in terms of death or MI that rivals those of CABG [7-13]. Over the last 20 years, advancement of PCI technique, improvement of stent technology and adjuvant drug therapy has led to progressively improved PCI outcomes for LMCA disease [13].

In Bangladesh death due to cardiovascular disease is the top most cause of death. With advancing image modalities & newer generation DES, many centers are routinely practicing left main intervention with favorable outcome. Here we present our experience PCI in ILMCA from single centre tertiary care hospital in Gazipur, Bangladesh using DES.

## METHODS AND METHODOLOGY

This prospective observational study was carried out for 1 year between '01st February 2021 to 31st January 2022' at Sheikh Fazilatunnessa Mujib Memorial KPJ Specialized Hospital, Gazipur, Dhaka, Bangladesh. A total of 10 patients presented with Angina or NSTEMI & whom CAG reveals isolated left main coronary artery diseases were enrolled for this study. Clinical parameters were recorded. SYNTAX score was calculated for all patients. Then after CAG, PCI to Left Main Coronary Artery was done with newer generation DES for all of these patients having ILMCA Stenosis. Standard techniques were applied for all the cases. Most of the pt got loading dose of Antiplatelets, UF Heparin & Eptifibatide during procedure. All patients were kept on DAPT, Aspirin 150 mg for all along with either Clopidogrel 75 mg or Prasugrel 10 mg. Follow up was done at 2 weeks, 6 weeks, 12 weeks & 24 weeks and outcome is noted.

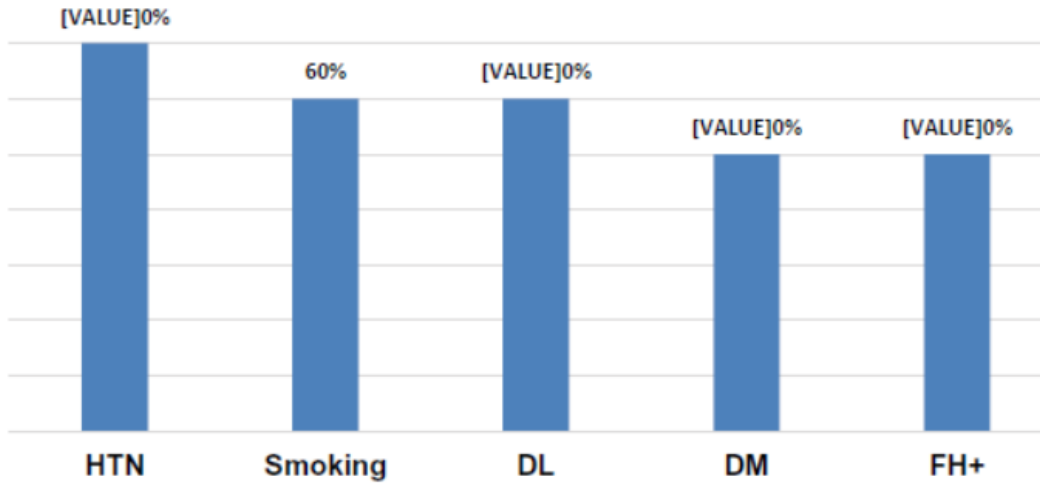
## RESULTS

A total of 10 patients with who have ILMCA stenosis found in angiogram & treated with DES were included in the study. Baseline patient characteristics and angiographic characteristics are recorded.

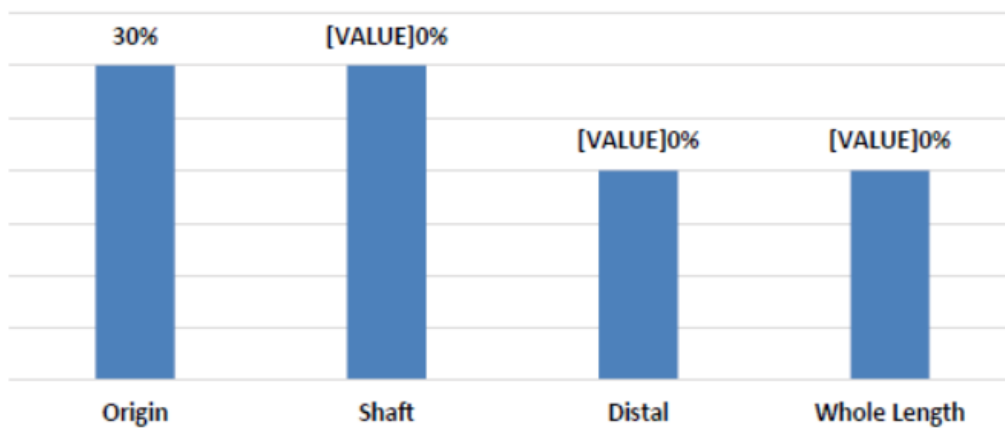
Mean age of the patients was  $44.1 \pm 6.6$  years. Among them male was 7 (70%), female was 3 (30%). Hypertension (70%) was the most common risk factor followed by smoking (60%), dyslipidemia (60%), diabetes mellitus (50%) and positive family history of IHD (50%) (Figure 1).

Among the total of 10 patients, 07 (70%) patients had chronic stable angina, 03 (30%) patients had NSTEMI.

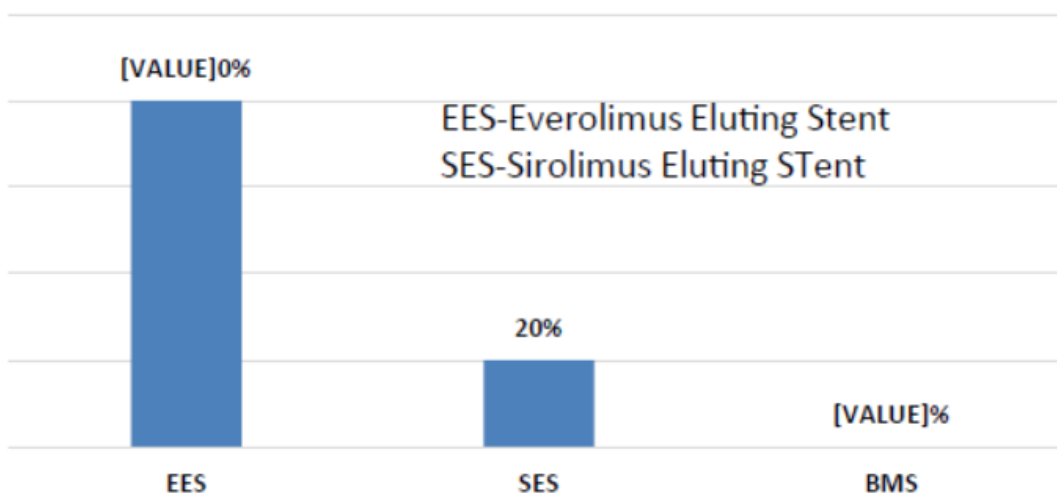
Good left ventricular systolic function was present in 8 (80%) patients and 2 (20%) patients had mild dysfunction, no moderate or severe left ventricular systolic dysfunction. Right dominant circulation was 80%, left dominant circulation was 20%. Ostial left main involvement in 03 (30%) patients, shaft involvement in 03 (30%) patients, 02 (20%) distal left main disease and whole segment disease in 02 (20%) patients (Figure 2).



**Figure 1.** Bar diagram showing risk factors.



**Figure 2.** Bar diagram showing site of involvement.



**Figure 3.** Bar diagram showing types of stents used.

Mean SYNTAX score of the study population was  $11.1 \pm 1.1$  with majority of patients having low SYNTAX

score. All patients were treated with DES implantation. Among them 8 (80%) were Everolimus Eluting Stent and 2 (20%) were Sirolimus Eluting Stent. No Bare Metal Stent was used (Figure 3).

The post procedural outcome was satisfactory. Intravascular Ultrasound (IVUS) was done only in one patient, but for financial and logistic issues IVUS cannot be done in other patients.

Nine patients were fine with no further symptoms upto 6 months follow up. One patient developed symptoms at the end of 4 months and he had H/O discontinuation of Antiplatelets without notification. Check CAG (coronary angiogram) was done for that patient, who reveals 30-40% stent thrombosis and POBA was done uneventfully. No patient developed any MACE during the study period.

## DISCUSSION

The LMCA is of importance as it supplies approximately two-thirds of the blood to the heart and almost 100% of the blood flow to the left ventricle. As a result severe LMCA disease will reduce flow in a large portion of the myocardium placing the patient at a risk for life threatening events of LV dysfunction and arrhythmia [14]. The LMCA differs from the other coronary arteries by its relatively greater elastic tissue content which can explain elastic recoil and high restenosis rate following balloon angioplasty [14].

Coronary artery bypass graft or percutaneous coronary Intervention is the well-known modalities in revascularizing the LM disease. The superiority of CABG and PCI is still debatable, and guideline recommendation has been updated time to time. Recent comparative studies of PCI and surgical revascularization for LM PCI, demonstrated that PCI may be an alternative to CABG in treating LMCA.

The study was conducted with the purpose of analyzing the ILMCA PCI patients in a real world scenario. During hospital stay, no patient had MACE. Several trials have presented outcomes of ILMCA PCI using DES over the recent years. Results reported in these studies vary widely due to variation in patient selection and procedural technique. Most of these studies have shown that lesions involving left main ostium and shaft have better outcomes than distal left main lesions in terms of MACE. Significantly higher MACE was demonstrated in emergent or urgent ILMCA PCI, whereas favorable short- and long-term outcomes were shown in elective ILMCA stenting. In our study, most of the patients had origin & shaft. In our study 02 patients had distal lesion. Among these both cases were managed with single stent strategy. No patient developed any peri-procedural major or minor adverse cardiac events like anginal chest pain, arrhythmias, cardiac arrest, cardiogenic shock, Q-wave MI, repeat revascularization and death during their hospital stay. So in this procedural success & in-hospital survival rate was excellent (100%). Though one patient developed symptoms at the end of 4 months possibly because he had discontinued Antiplatelets for his gastrointestinal problem. We have checked coronary which reveals 30-40% stent thrombosis & POBA was done uneventfully and after that patient was asymptomatic.

## CONCLUSION

In this study we have found that PCI to isolated left main coronary artery stenosis is a reasonable option. Isolated left main disease is an important predictor of cardiovascular mortality and morbidity. Numbers of studies have shown that PCI to left main coronary artery is non-inferior to CABG. With the use of newer generation DES, In Stent Restenosis (ISR) is significantly reduced with good outcome. Large scale multicenter study is needed to see long term outcome.

## REFERENCES

1. Proudfit, William L, Earl K Shirey and F. Mason Sones JR. "Distribution of arterial lesions demonstrated by selective cinecoronary arteriography." *Circulation* 36 (1967): 54-62.

2. Cohen, Micheal V., P. F. Cohn, M. V. Herman and R. Gorlin. "Diagnosis and prognosis of main left coronary artery obstruction." *Circulation* 45 (1972): 157-165.
3. Park, Seung-Jung, Young-Hak Kim, Bong-Ki Lee and Seung-Whan Lee, et al. "Sirolimus-eluting stent implantation for unprotected left main coronary artery stenosis: Comparison with bare metal stent implantation." *J Am Coll Cardiol* 45 (2005): 351-356.
4. Kim, Young-Hak, Duk-Woo Park, Seung-Whan Lee and Sung-Cheol Yun, et al. "Long-term safety and effectiveness of unprotected left main coronary stenting with drug-eluting stents compared with bare-metal stents." *Circulation* 120 (2009): 400-407.
5. Erglis, Andrejs, Inga Narbute, Indulis Kumsars and Sanda Jegere, et al. "A randomized comparison of paclitaxel-eluting stents versus bare-metal stents for treatment of unprotected left main coronary artery stenosis." *J Am Coll Cardiol* 50 (2007): 491-497.
6. Tamburino, Corrado, Maria Elena Di Salvo, Davide Capodanno and Tullio Palmerini, et al. "Comparison of drug-eluting stents and bare-metal stents for the treatment of unprotected left main coronary artery disease in acute coronary syndromes." *Am J Cardiol* 103 (2009): 187-193.
7. Buszman, Pawel E., Stefan R. Kiesz, Andrzej Bochenek and Ewa Peszek-Przybyla, et al. "Acute and late outcomes of unprotected left main stenting in comparison with surgical revascularization." *J Am Coll Cardiol* 51 (2008): 538-545.
8. Boudriot, Enno, Holger Thiele, Thomas Walther and Christoph Liebetrau, et al. "Randomized comparison of percutaneous coronary intervention with sirolimus-eluting stents versus coronary artery bypass grafting in unprotected left main stem stenosis." *J Am Coll Cardiol* 57 (2011): 538-545.
9. Park, Seung-Jung, Young-Hak Kim, Duk-Woo Park and Sung-Cheol Yun, et al. "Randomized trial of stents versus bypass surgery for left main coronary artery disease." *N Engl J Med* 364 (2011): 1718-1727.
10. Kappetein, Arie Pieter, Ted E. Feldman, Michael J. Mack and Marie-Claude Morice, et al. "Comparison of coronary bypass surgery with drug-eluting stenting for the treatment of left main and/or three-vessel disease: 3-year follow-up of the SYNTAX trial." *Eur Heart J* 32 (2011): 2125-2134.
11. Chieffo, Alaide, Nuccia Morici, Francesco Maisano and Erminio Bonizzoni, et al. "Percutaneous treatment with drug-eluting stent implantation versus bypass surgery for unprotected left main stenosis: a single-center experience." *Circulation* 113 (2006): 2542-2547.
12. Palmerini, Tullio, Antonio Marzocchi, Cinzia Marrozzini and Paolo Ortolani, et al. "Comparison between coronary angioplasty and coronary artery bypass surgery for the treatment of unprotected left main coronary artery stenosis (the Bologna Registry)." *Am J Cardiol* 98 (2006): 54-59.
13. Palmerini, Tullio, Fabio Barlocco, Andrea Santarelli and Letizia Bacchi-Reggiani, et al. "A comparison between coronary artery bypass grafting surgery and drug eluting stent for the treatment of unprotected left main coronary artery disease in elderly patients (aged? 75 years)." *Eur Heart J* 28 (2007): 2714-2719.
14. Lee, Pil Hyung, Jung-Min Ahn, Mineok Chang and Seunghee Baek, al. "Left main coronary artery disease: Secular trends in patient characteristics, treatments, and outcomes." *J Am Coll Cardiol* 68 (2016): 1233-1246.